DEPARTMENT OF ANATOMY
UNIVERSITY OF AGRICULTURE
FAISALABAD

BOVINE UDDER

ANATOMICAL AND PHYSIOLOGICAL CONSIDERATIONS

Keynote Address

PROF DR ANAS SARWAR QURESHI

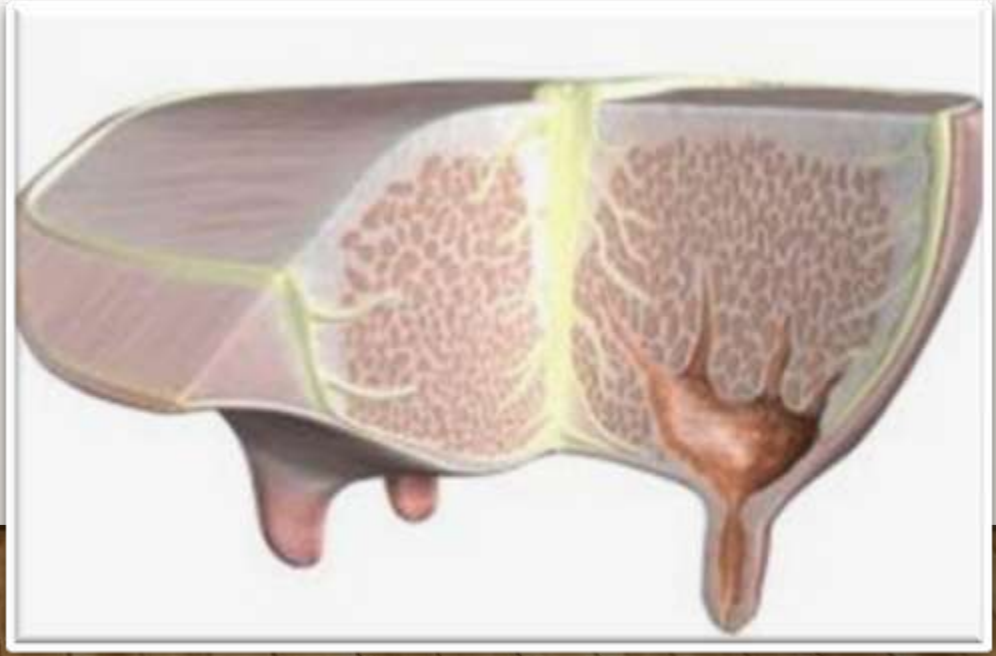

2ND Annual Bovine Udder Health Symposium
November 27, 2019 at UVAS

THE DEVELOPMENT OF THE MAMMARY GLAND

- Starts early in the fetal life.
- Already in the **second month of gestation** teat formation starts and the development continues up to the **sixth month of gestation**. When the calf fetus is six months, the udder is almost fully developed with four separate glands and a medial ligament, teat and gland cisterns.
- The development of milk ducts and the milk secreting tissue take place **between puberty and parturition**. The udder continues to increase in cell size and cell numbers throughout the **first five lactations of the cow**, and the milk production capacity increases correspondingly.

GROSS ANATOMY OF MAMMARY GLAND

- Mammary glands of domestic species have inguinal location with distinct right and left halves, and each half has a front and hind quarter which is independent from its counterpart with regard to its blood and nerve supply, lymphatic drainage and **suspensory apparatus**.
- A longitudinal furrow marks the ventral separation of the two halves. However, there are some variations in shape, length and diameter of teats from species to species.

GROSS ANATOMY OF MAMMARY GLAND

- A strong udder **suspensory system** is required to maintain proper attachments of the gland to the body.
- The mammary gland is a skin gland, and is external to the body cavity.
- A Holstein cow may have 50 kg of weight hanging from her body when she walks into the milking parlor to be milked. So the system of ligaments and other tissues which attach the udder to the cow are critical for successful lactation.

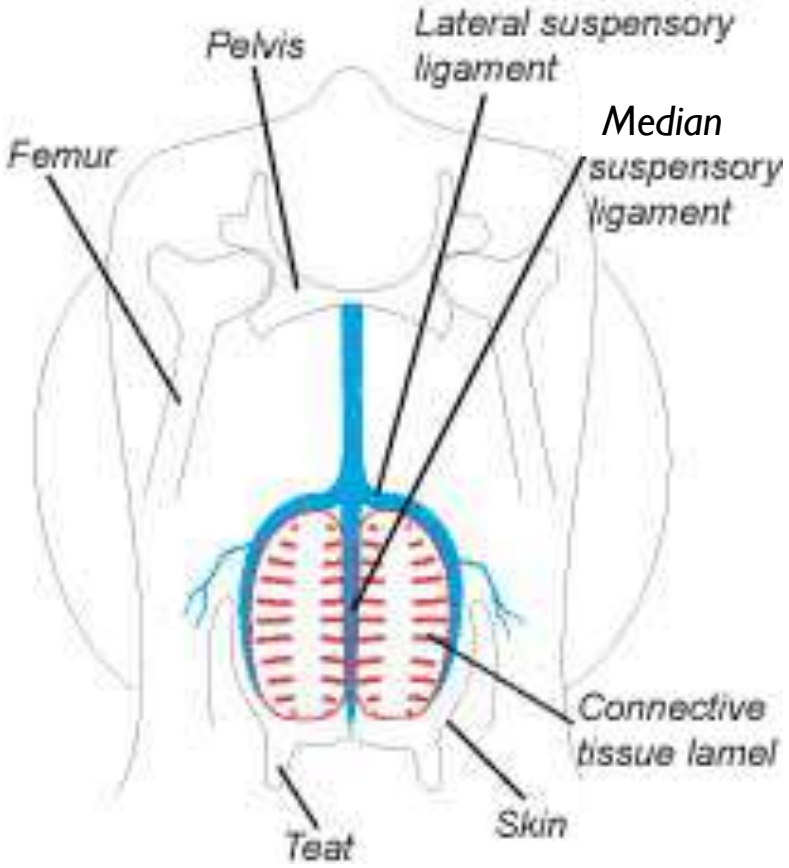
Pelvis
Lateral suspensory ligament
Median suspensory ligament
Femur
Connective tissue lamel
Skin
Teat

Comparison of the morphologies of mammary glands of different species

Species	Shape of mammary gland	Number of teats	Location	Length of teat (cm)	Diameter of teat (cm)	No of streak canals	Streak canal length	References
Buffalo	Ellipsoidal in form but flattened transversely	4	Pelvic	7-8	1		7.5 -13.0	Uppal et al 1995
Cow	Same as in buffalo	4	Pelvic	7.5-10	1		3-13	Nickerson, 1995/Anderson (1985)
Camel	Cone shaped	4	Inguinal	2.38-2.14	2			Kausar and Qureshi, 2001
Sheep/ Goat	Globular	2	Pelvic		1			William, 1997
Mare	Short flattened cone much compressed transversely	2	Inguinal		2			William, 1997

Species characteristics

- Cow
- Camel

- Ewe
- Goat
- Mare

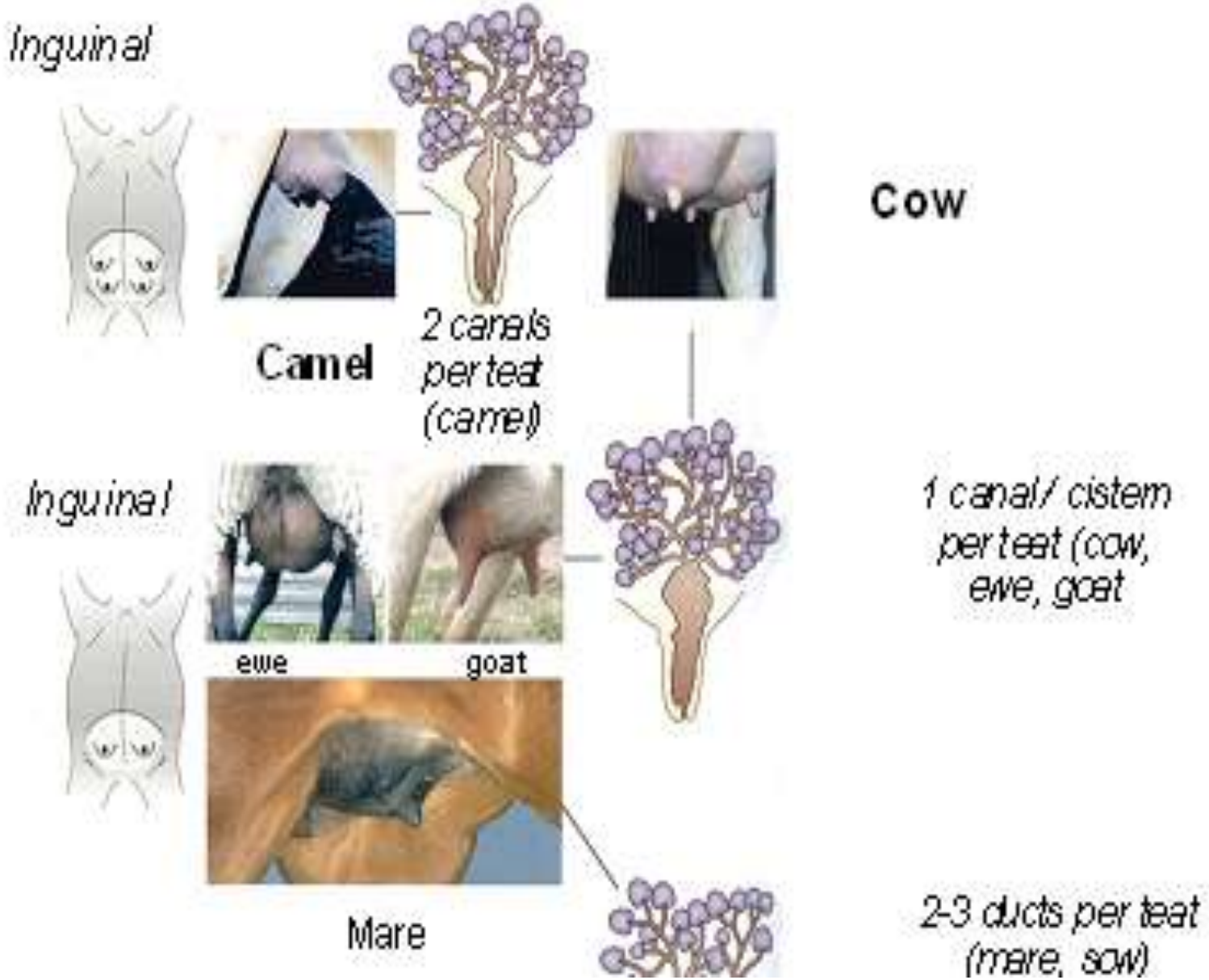

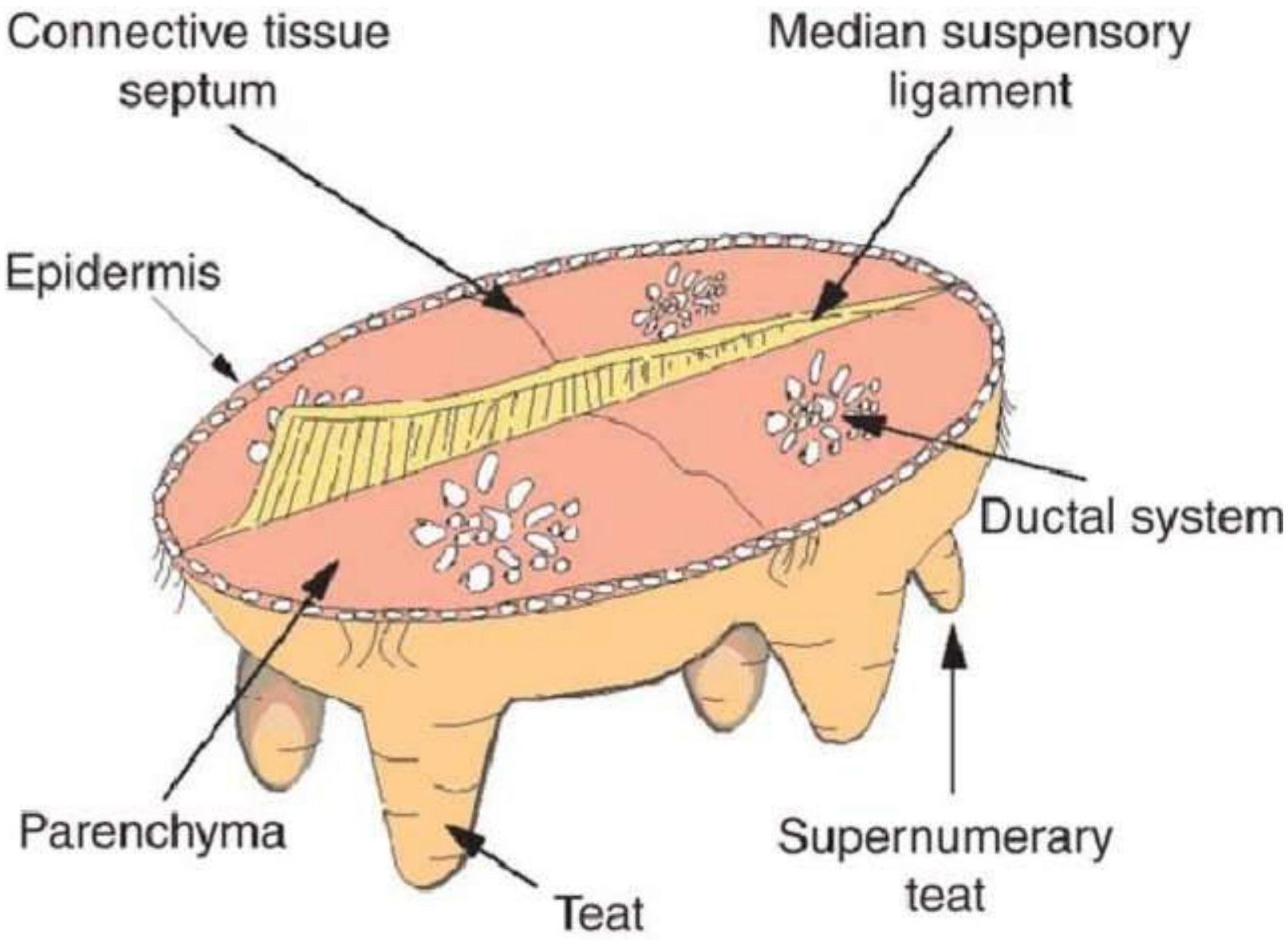
Connective tissue septum
Median suspensory ligament
Epidermis
Ductal system
Parenchyma
Supernumerary teat
Teat

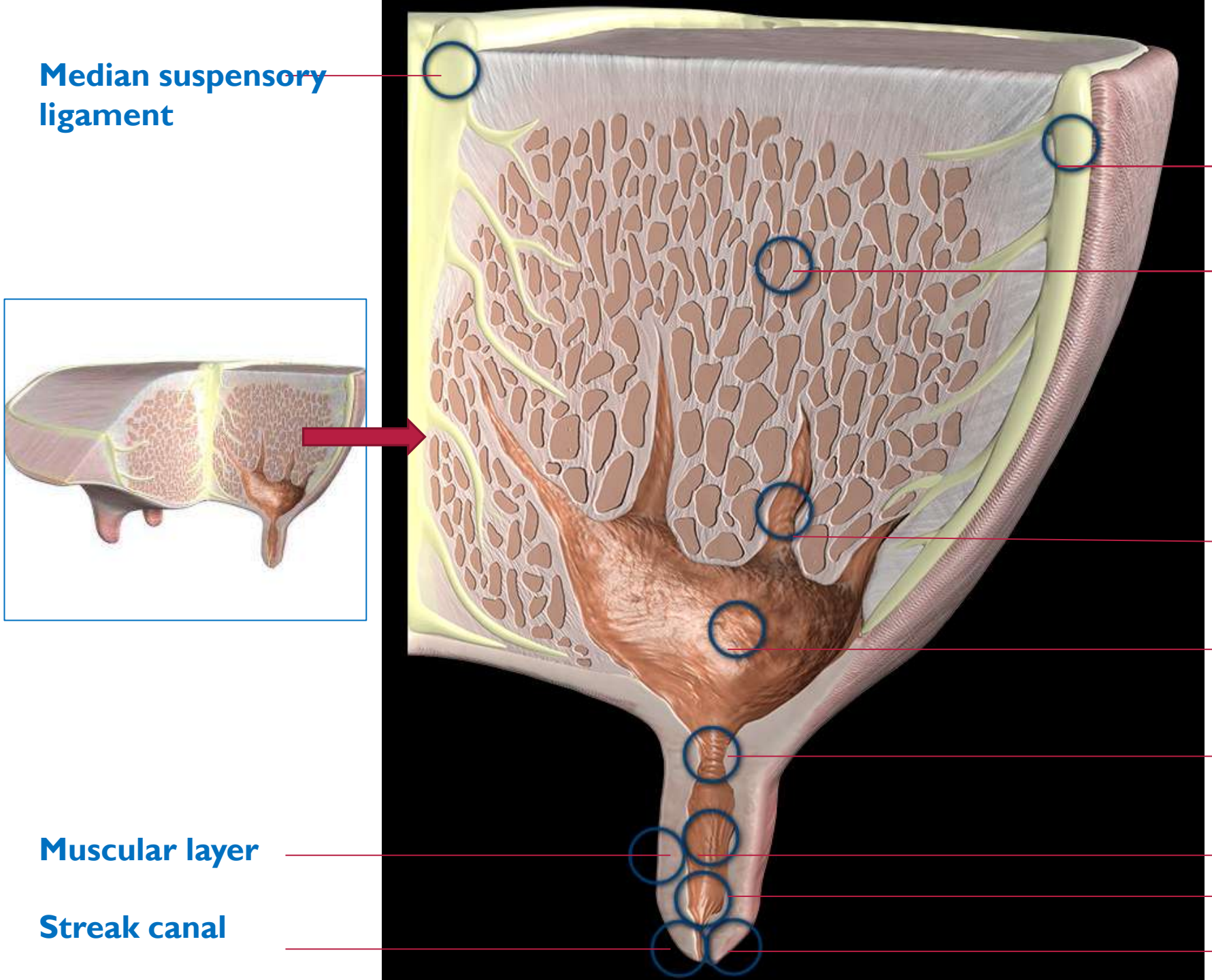
Median suspensory ligament
Lateral suspensory Lig.
Parenchymal tissue
Interlobar ducts
Udder cistern
Duct connecting udder cistern with teat
Muscular layer
Teat cistern
Furstenberg's rosette
Streak canal
Teat sphinctor

FURSTENBERG'S ROSETTE

The **Furstenberg's rosette** is located in the internal streak canal of the teat. It radiates upward into the teat cistern. It often is considered a barrier for pathogens, yet it offers little resistance to milk leaving the teat.

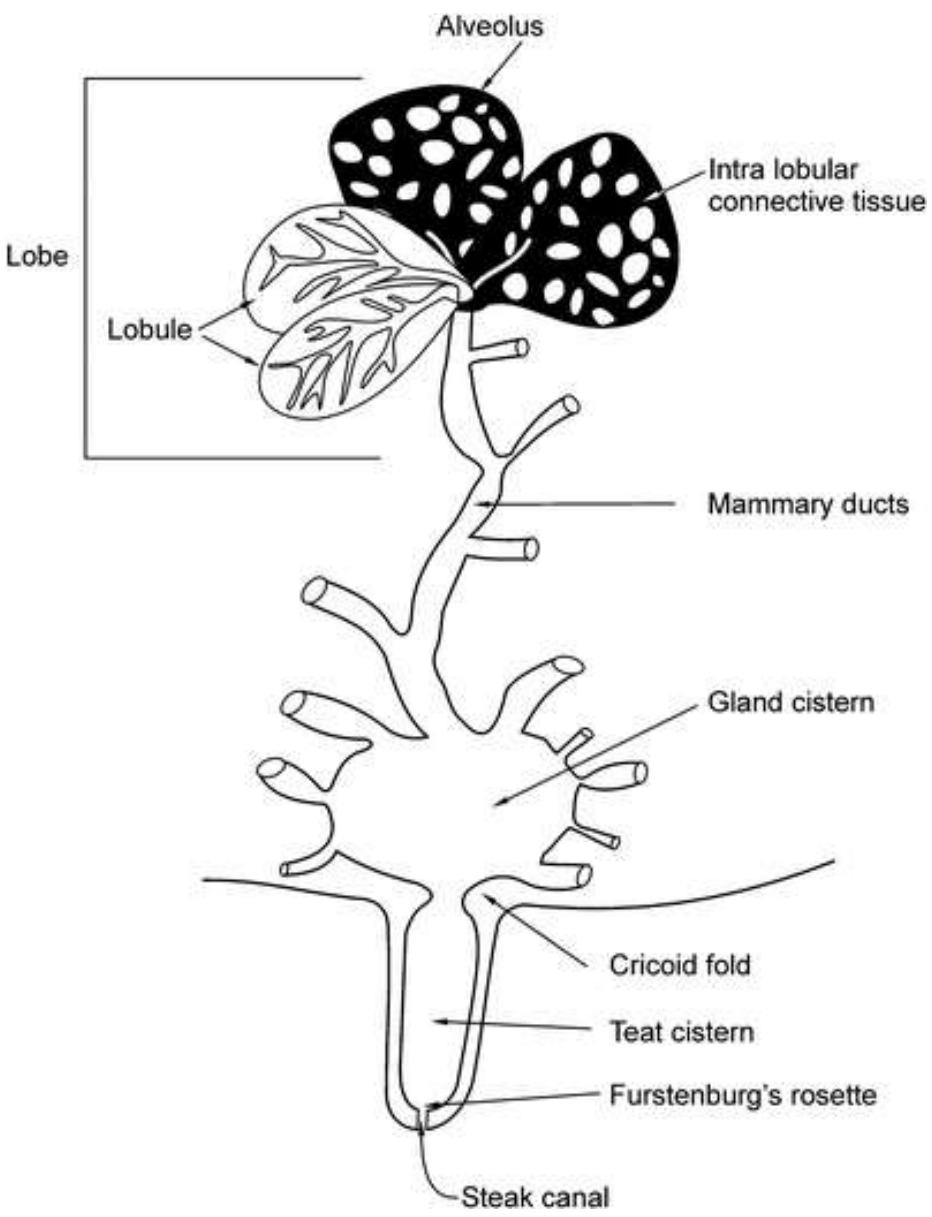

CORPORA AMYLACEA

- Concretions of casein and cell detritus, are common in advanced stages of lactation.
- During gestation they are located outside of the alveoles and in the interalveolar connective tissue.
- Only in very few cases corpora amylacea are found inside and outside of the alveoles in the same mammary glands.

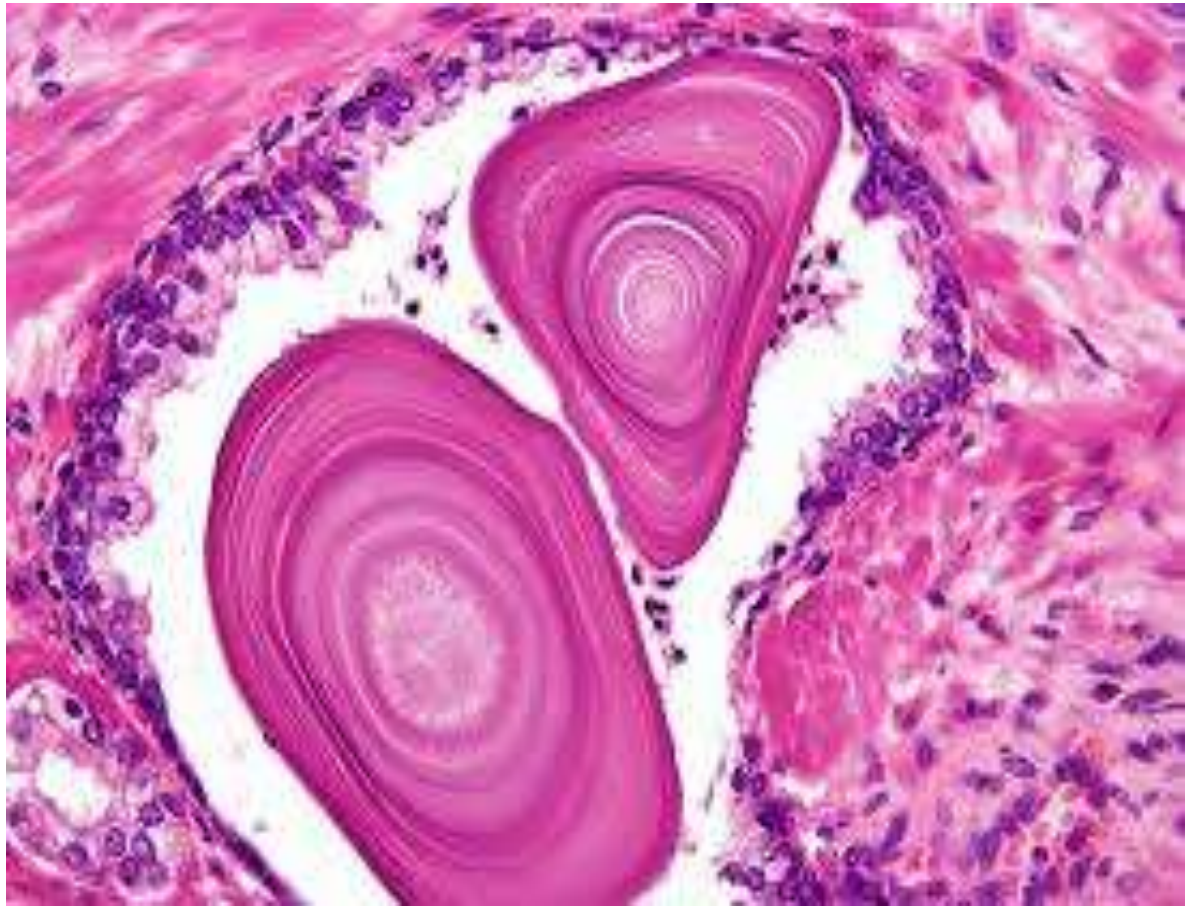

THE LACTATING UDDER

- The secretory units are alveoli, which are lined by a cuboidal or columnar epithelium.
- A layer of myoepithelial cell is always present between the epithelium and the basement membrane of the branches, lactiferous duct and the alveoli.
- Secretion of milk proteins proceeds by exocytosis (merocrine secretion) whereas lipids are secreted by apocrine secretion.
- Colostrum is the first formed milk rich in
- Ig-E immunoglobulins . It is yellow in color.

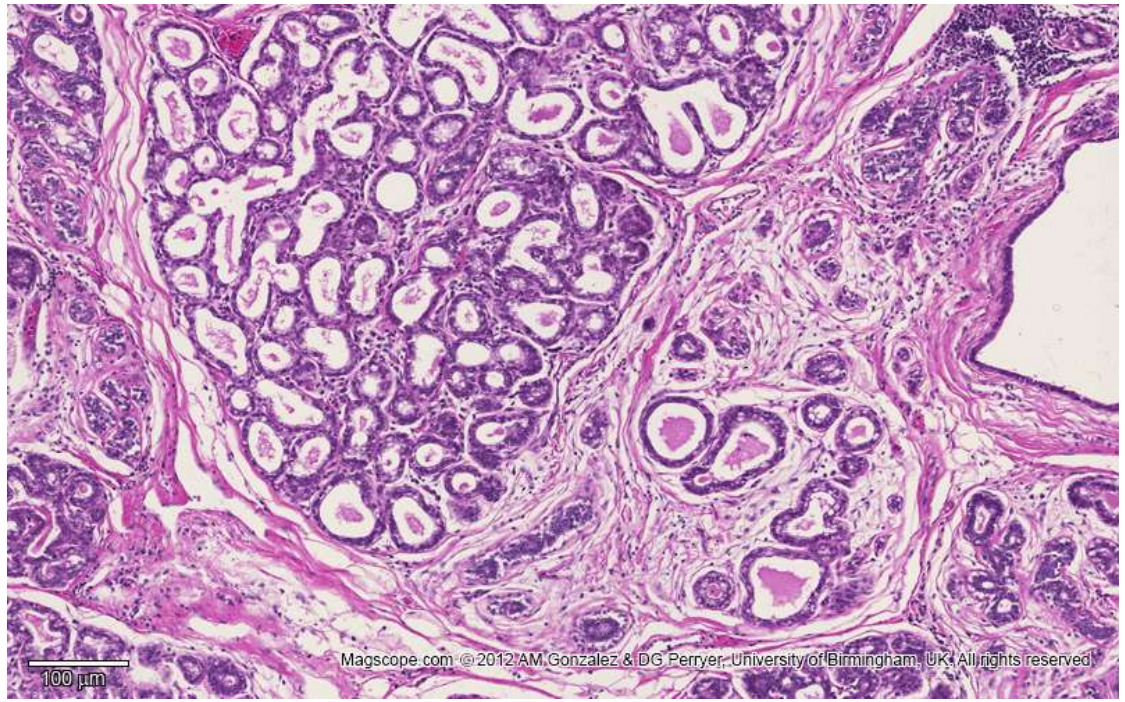

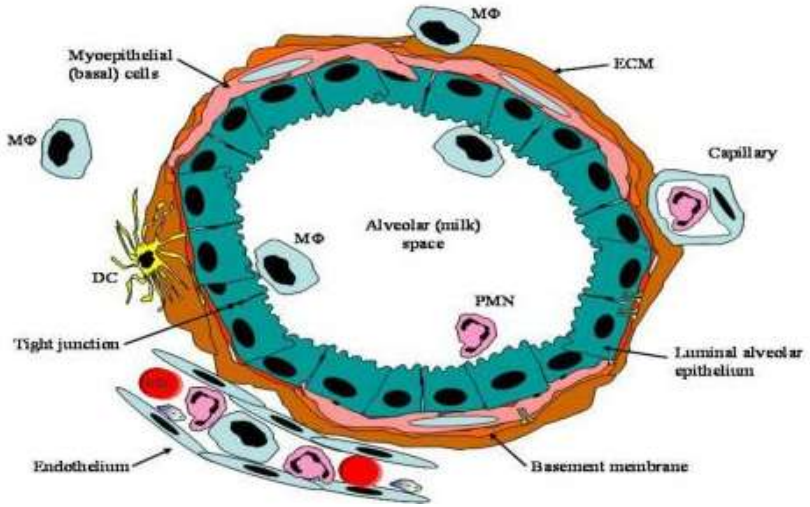

GLOMUS ORGANS (HOYER-GROSSER'S ORGANS)

Glomus organs (Hoyer-Grosser's organs) are frequently found in the **corium** and the **subcutis** of the skin of the equine and bovine mammary gland.

They are most frequently situated in the border zone between the stratum profundum and the stratum superficiale corii.

The glomus organs vary in size and shape, they possess common histologic structures: an arteriole enter the connective capsule of the glomus and divided into strongly convoluted arterio-venous channels; the arteriovenous channels unite in the end to form a venule; the vascular elements cover by a connective capsule and are thus united to an organ-like structure.

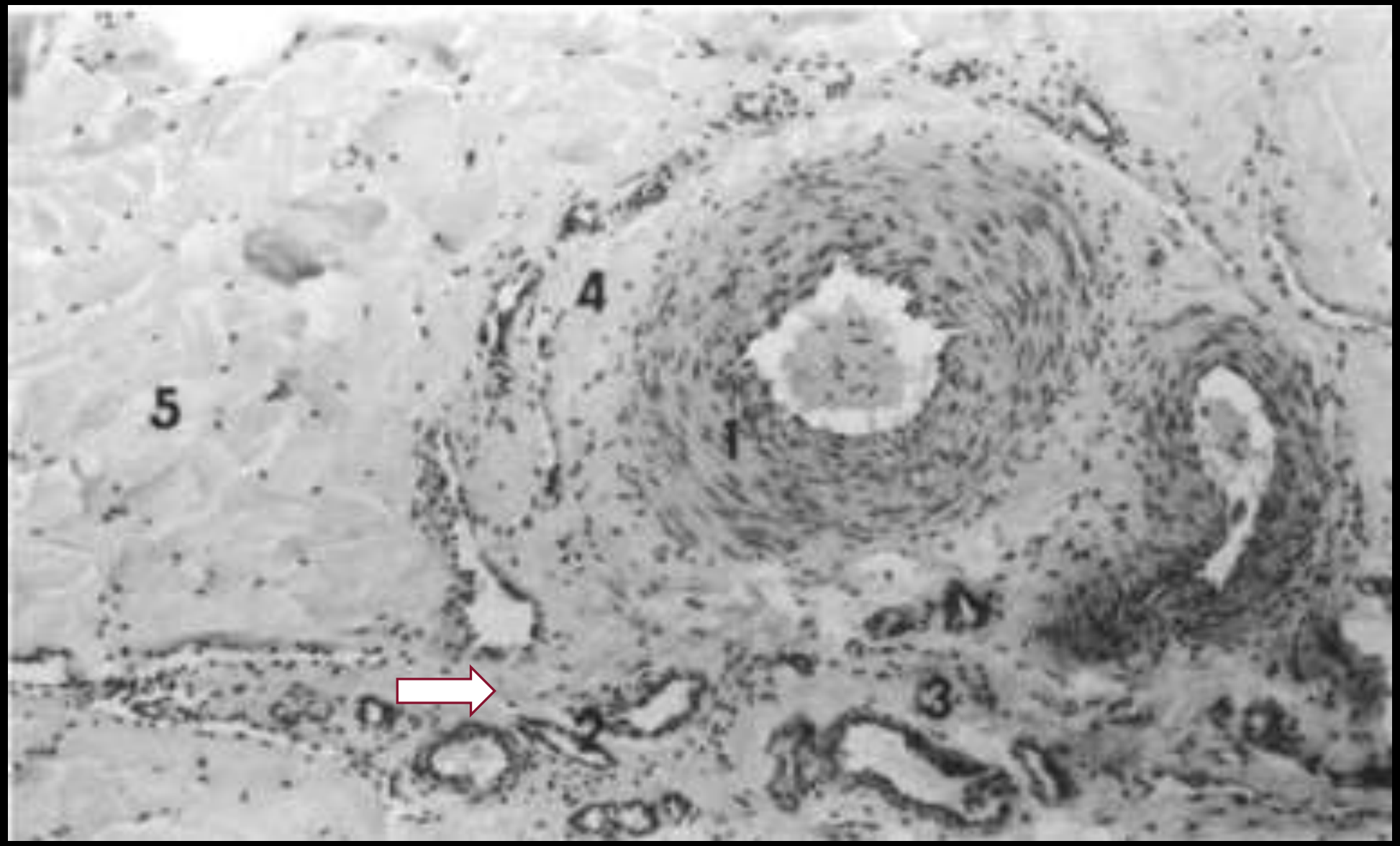

Glomus organ of the cow. Muscular artery (l), arterio-venous channels (2), nerve fascicle (3), capsule of connective tissue (4), collagen fibres (5)

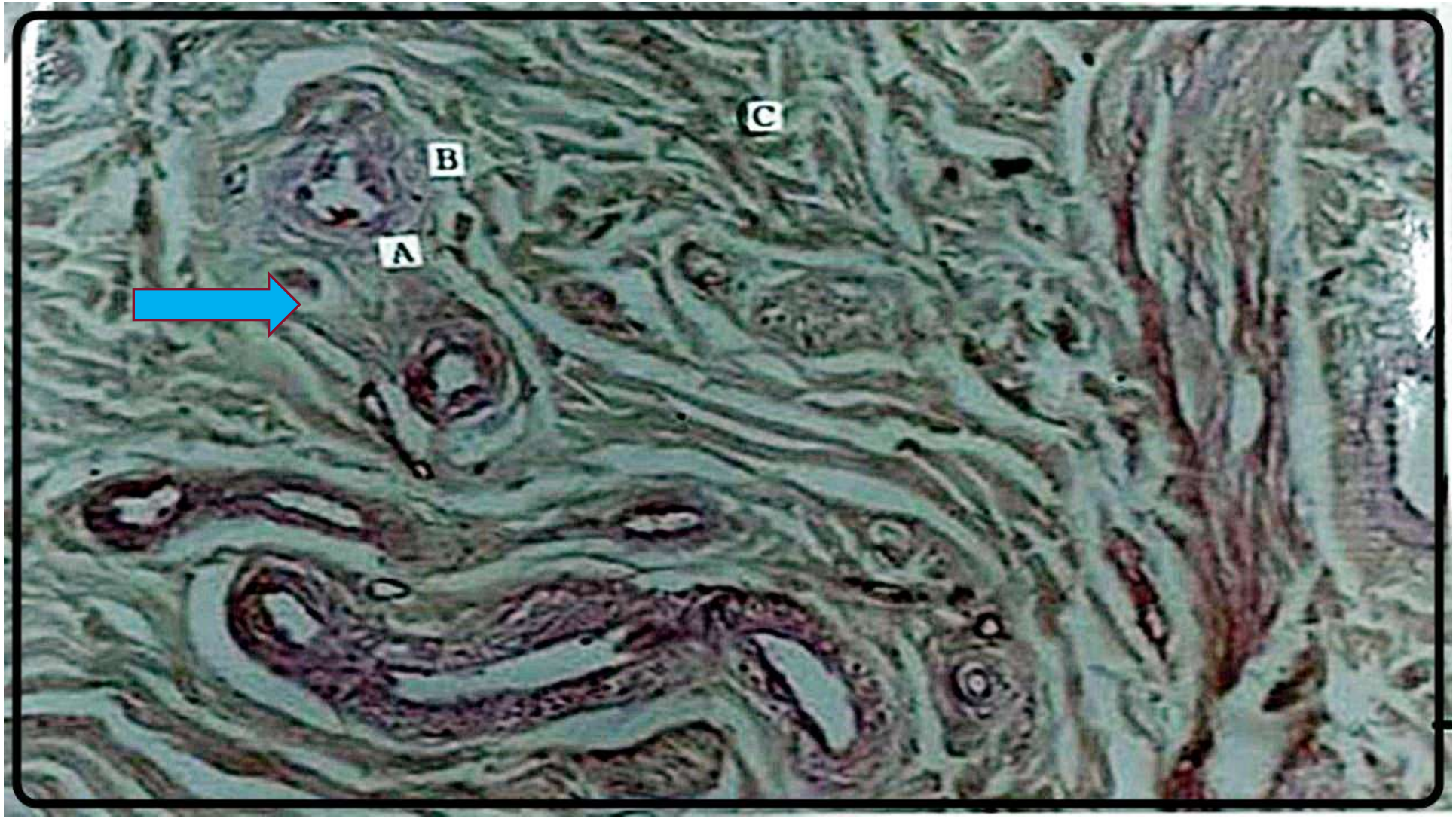

Glomus organs in the cutis of skin from bovine mammary gland. A. Glomus organs (Arterio-Venous anastomosis) B. Capsule, C. Connective Tissue

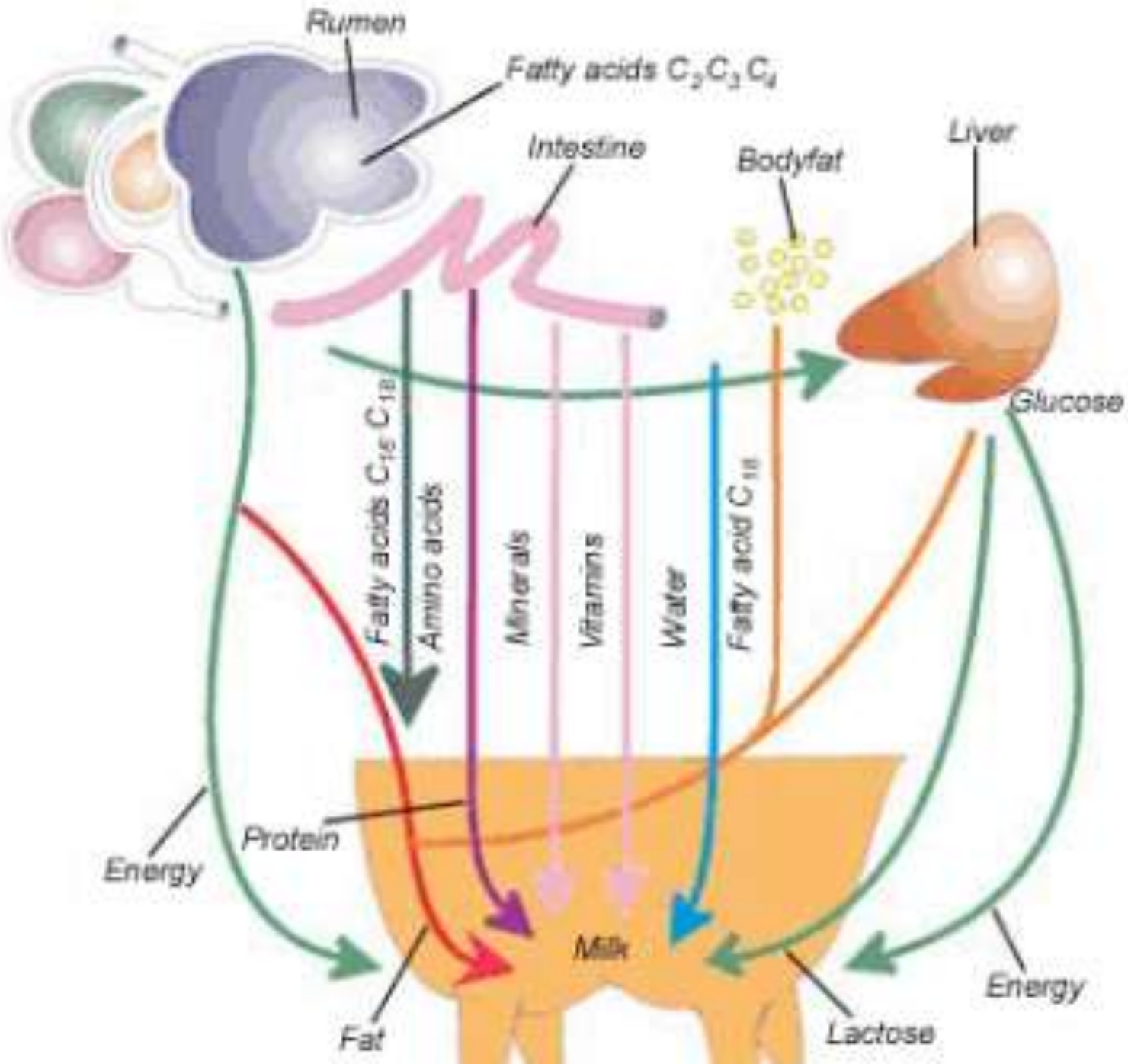
Rumen
Fatty acids $C_2 C_3 C_4$
Intestine
Bodyfat
Liver
Glucose
Fatty acids C_{18} C_{18}
Amino acids
Minerals
Vitamins
Water
Fatty acid C_{18}
Protein
Energy
Milk
Fat
Lactose
Energy

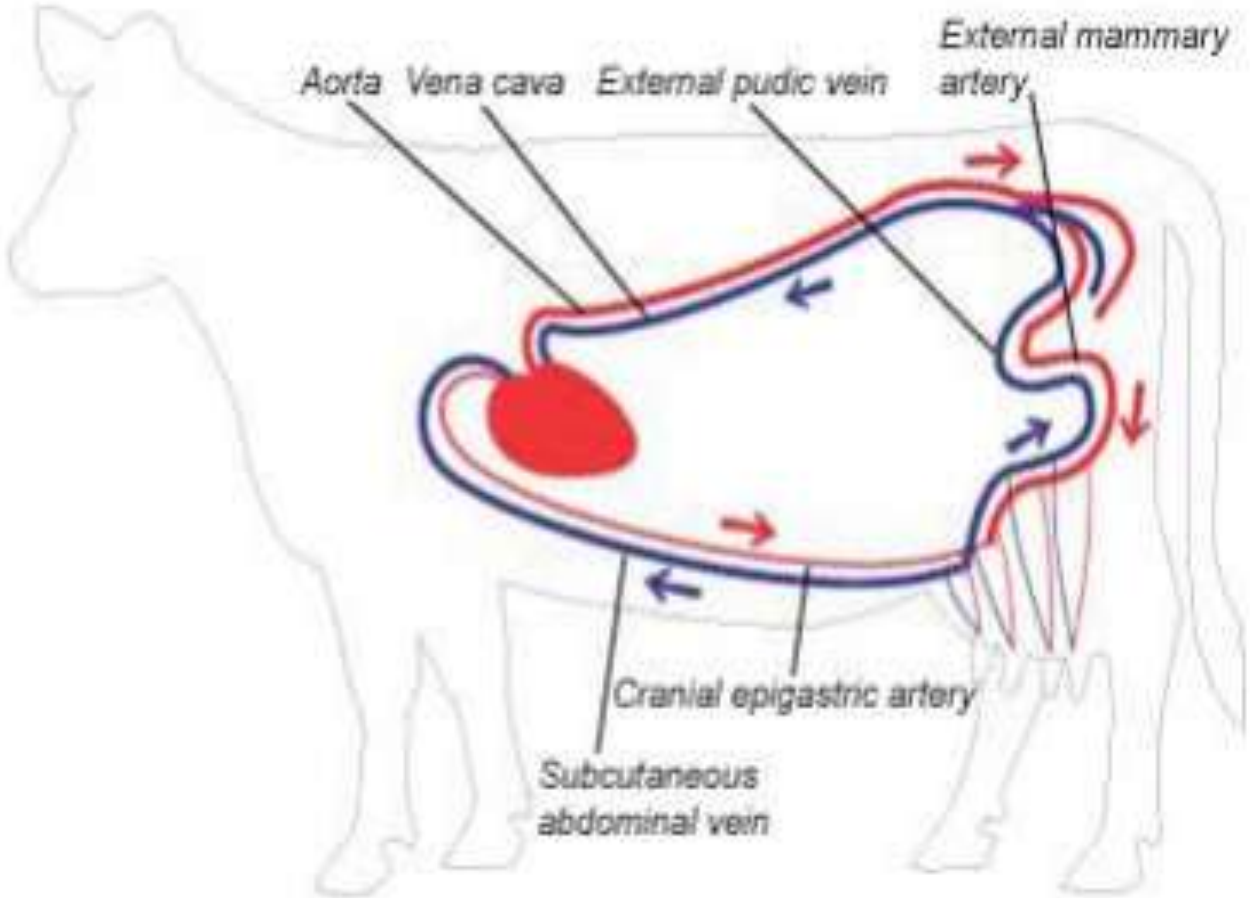

For a cow to produce 40 pounds of milk per day, approximately 8 tons of blood must pass through the udder. This amount of milk is produced, secreted, suspended, and removed from the udder in a short milking period from a sac of tissue weighing about 50 pounds.

DRY PERIOD

The bovine dry period is a non-lactating period between consecutive lactations characterized by mammary gland involution and redevelopment phases to replace senescent mammary epithelial cells with active cells primed for the next lactation.

Primiparous and multiparous females differ in mammary gland alveolar development: Implications for milk production

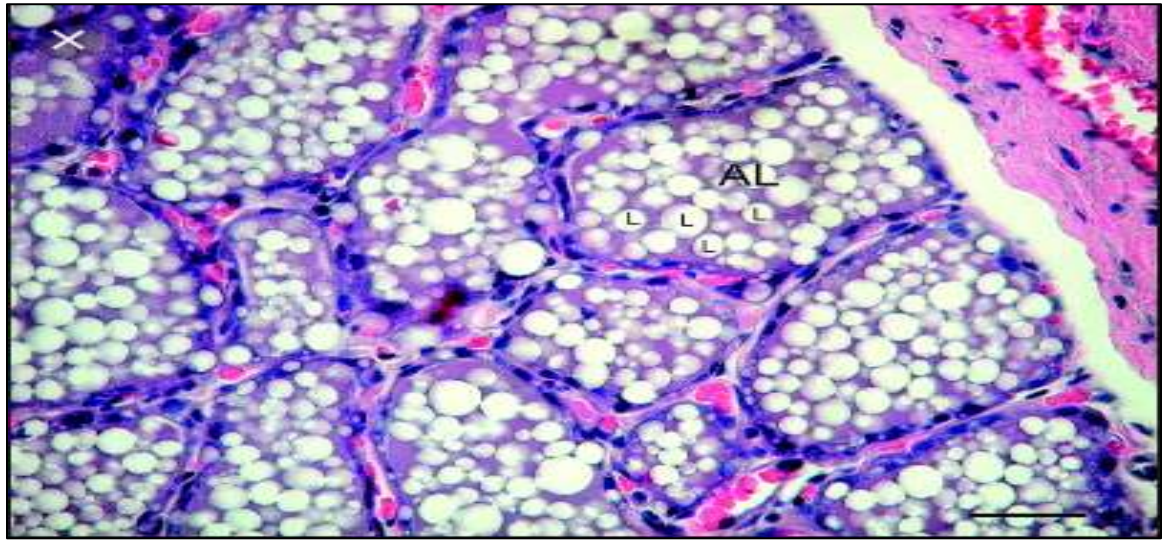

The mammary gland of primiparous females may have both a lower secretory capacity and a lower storage capacity on a relative basis than those of multiparous females and demonstrate, for the first time, that reproductive experience has a significant effect on both the rate and pattern of mammary gland alveolar development and, potentially, on a female's capacity for milk production.

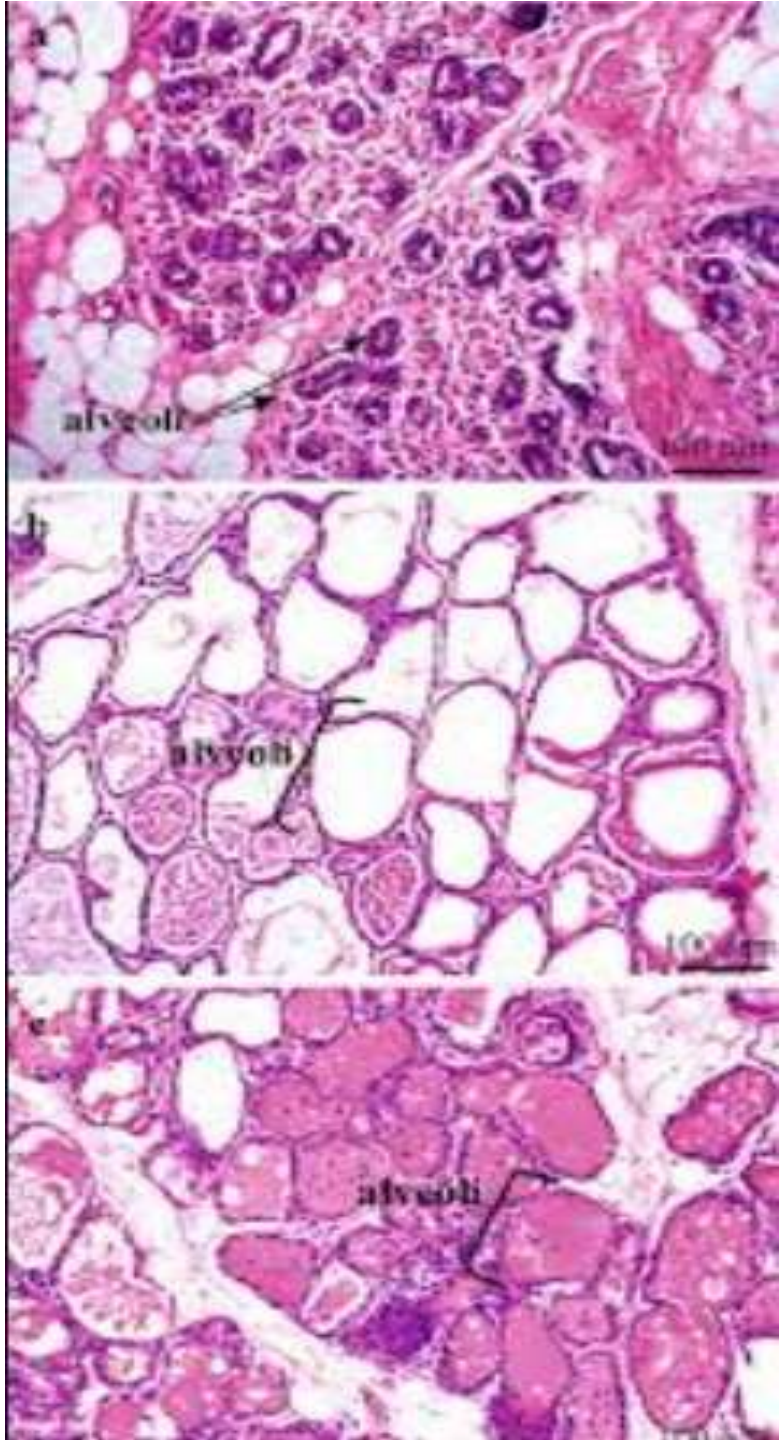

Pregnant

Lactating & nursing

Lactating

H&E; 200X

Dry period heat stress induces microstructural changes in the lactating mammary gland

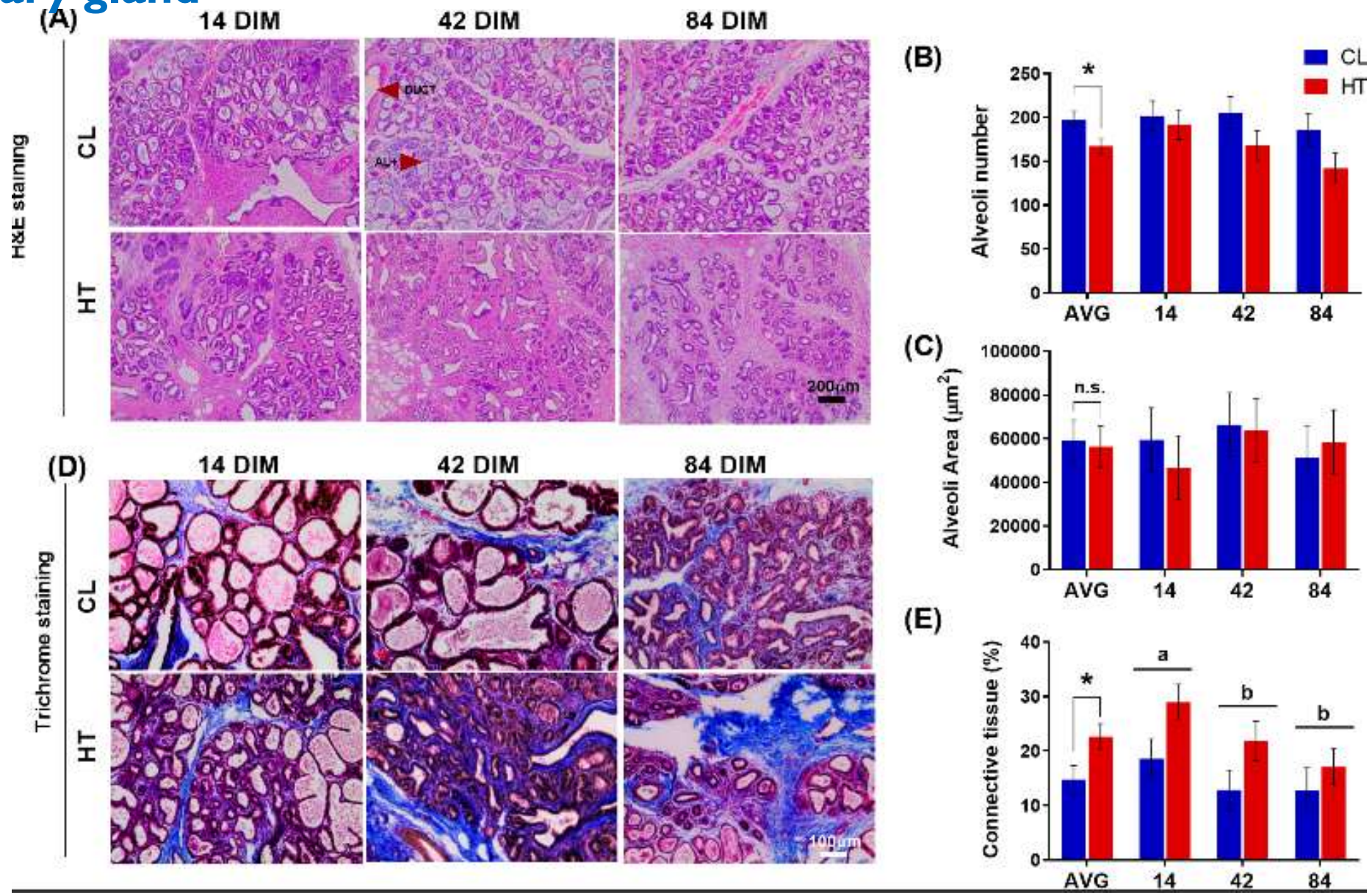

HEALTHY *vs* CLINICALLY MASTITIC MAMMARY GLAND

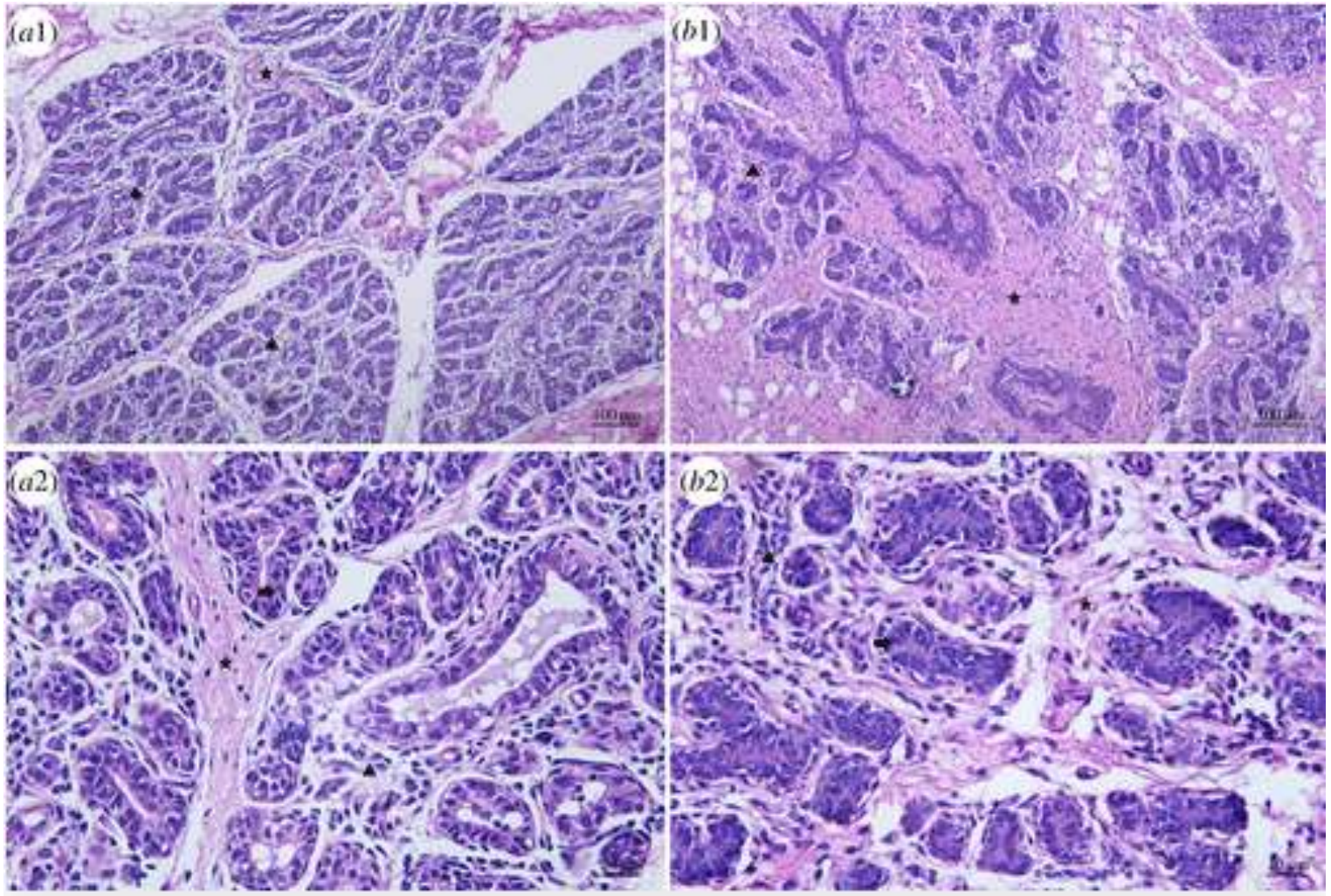

Sheep
H&E; 100X; 400X

NATURAL DEFENSE MECHANISMS OF UDDER

- Several defense mechanisms for prevention of infection by mastitis pathogens exist within the udder.
- **First line of defense** is the streak canal, which serves as a valve to control milk flow and to prevent the entrance of bacteria.
- **Second line of defense** composed of mammary secretions. These include the enzyme lysozyme, the lactoperoxidase/Thiocyanate hydrogen peroxide system, lactoferrin, complement components, various types of Immunoglobulins and leukocytes. The concentration of lysozyme in human milk is 3000 times greater than the cattle. The low concentration of lysozyme in cattle may represent a weakness in the second line of defense against bacteria.

CONCLUSION

A healthy mammary gland is one the basis of commercial dairy products, in terms of quality and quantity.

Thank you